Long-term Coronary Problems in Adult Patients after Kawasaki Disease

Teiji Akagi, MD, PhD, FACC, FAHA
Adult Congenital Heart Disease Center
Okayama University
Okayama, Japan

OKAYAMA UNIV.

Nationwide Survey of KD in Japan

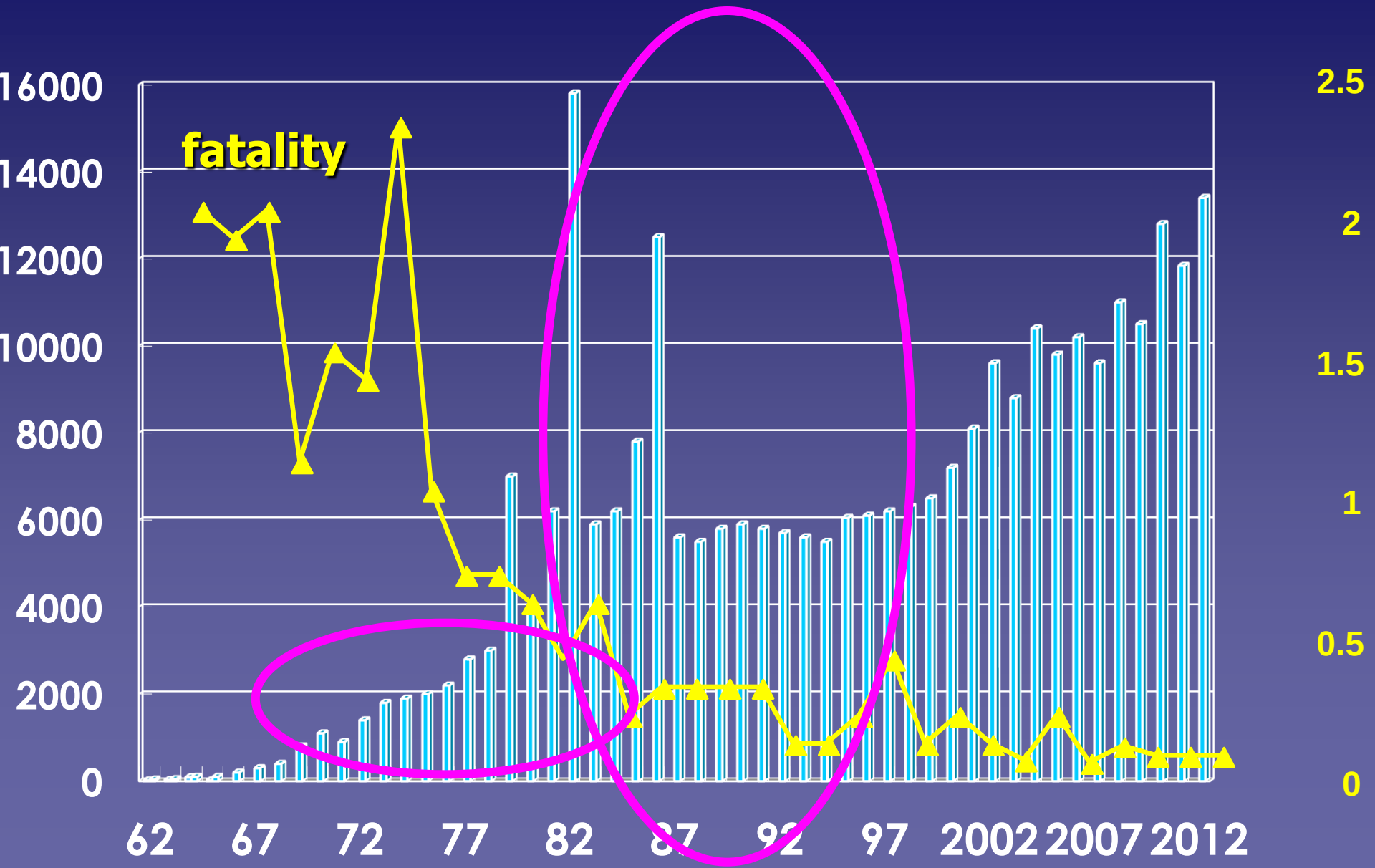

Incidence of Coronary Artery Lesions

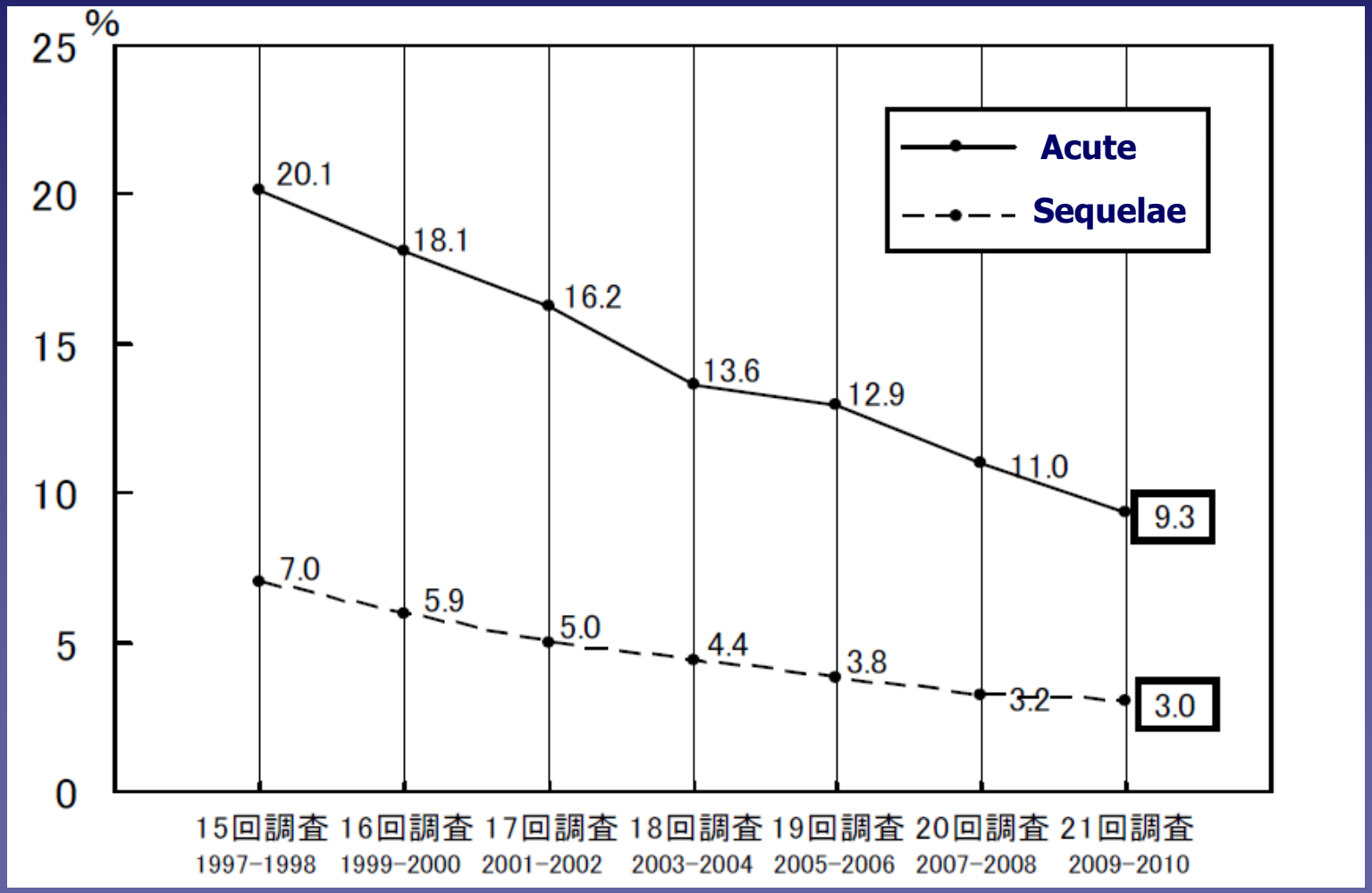

Morphology of coronary aneurysm changes by aging

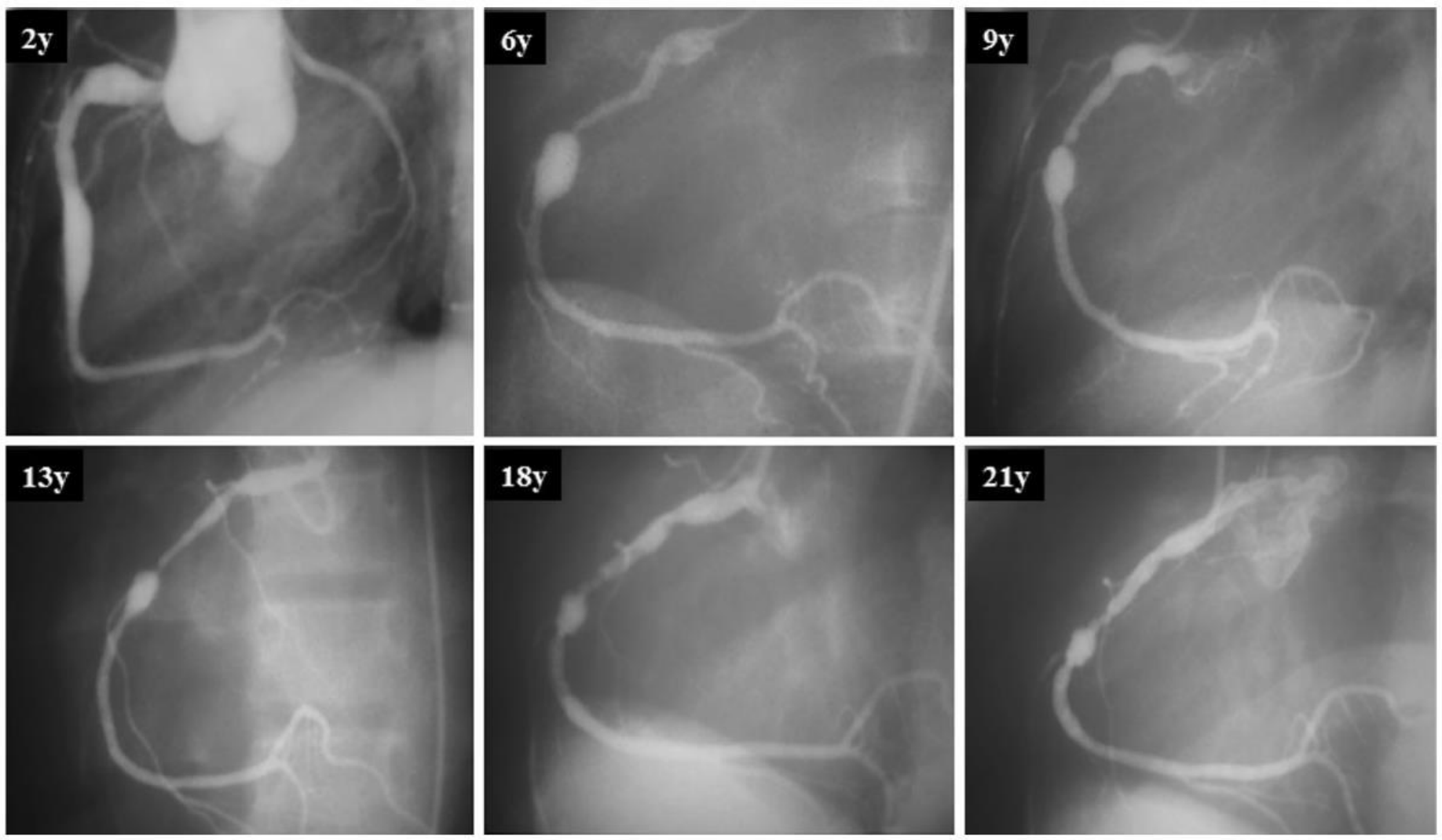

Fate of Coronary Aneurysm in KD

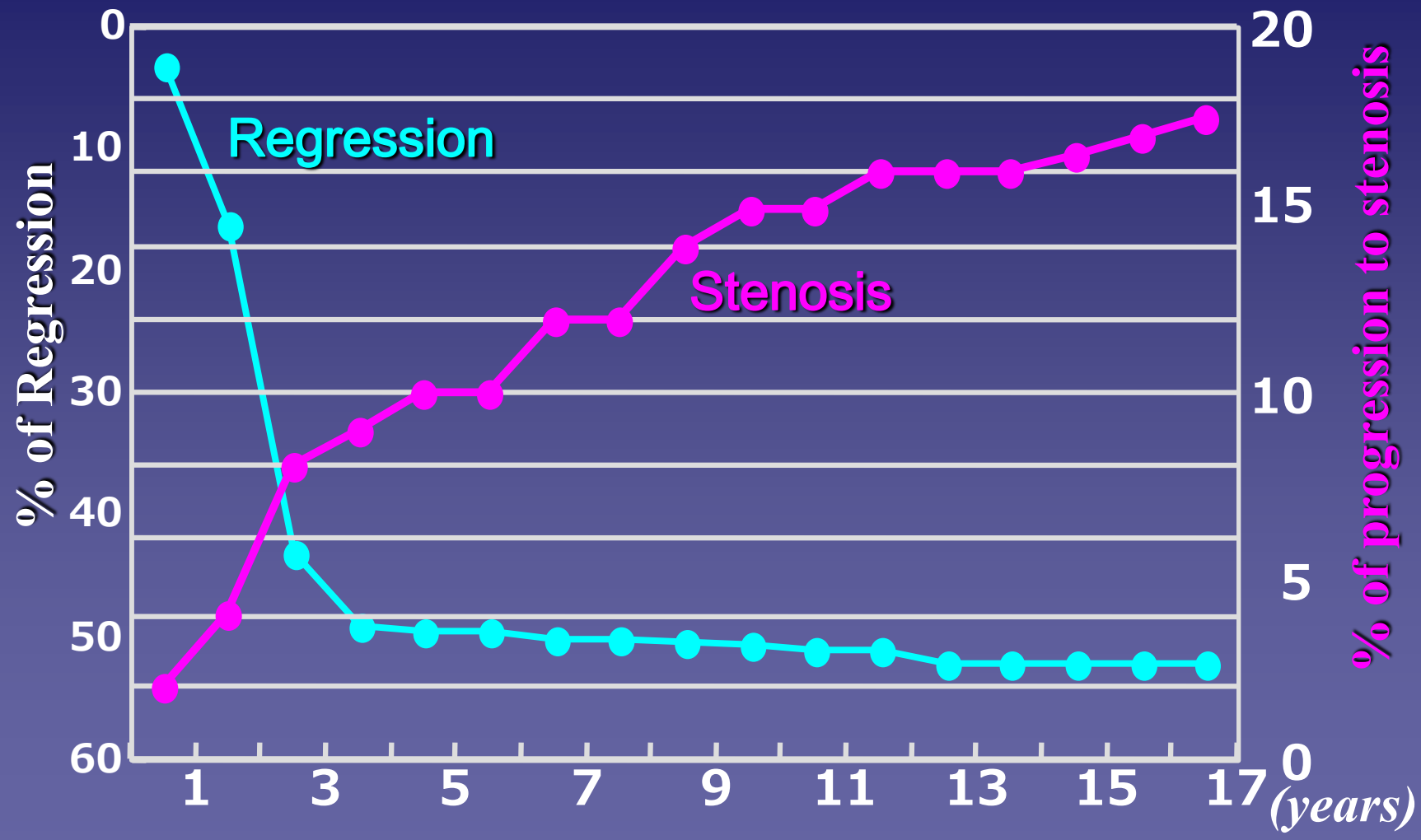

Kato H, Akagi T, et al. Circulation 1996; 94: 1379

Prognostic Factors of Coronary Aneurysms

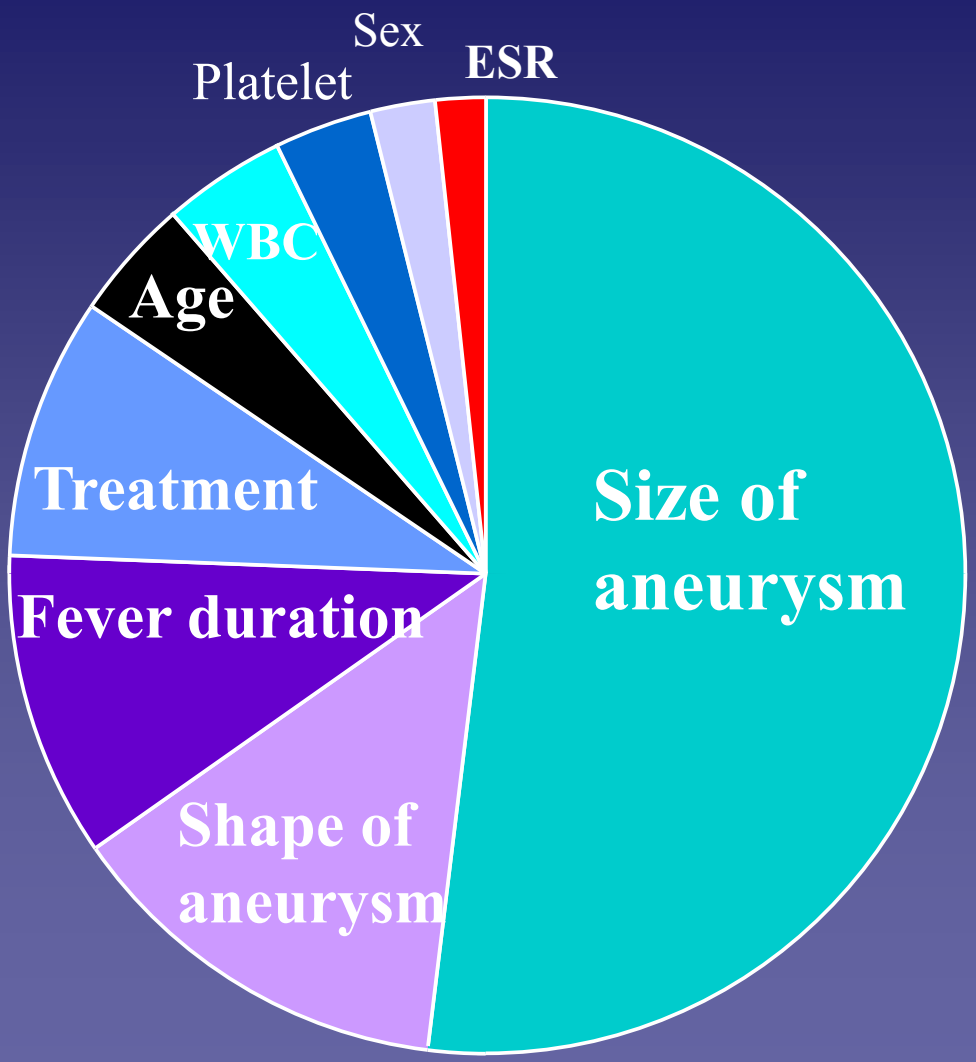

Risk factors:

* Size of aneurysm >8mm in diameter
* Shape of aneurysm large diffuse or saccular type
* Fever >3 weeks
* Treatment, steroid > aspirin
* Age > 2 yrs

Long-Term Prognosis of Patients With Kawasaki Disease Complicated by Giant Coronary Aneurysms

A Single-Institution Experience

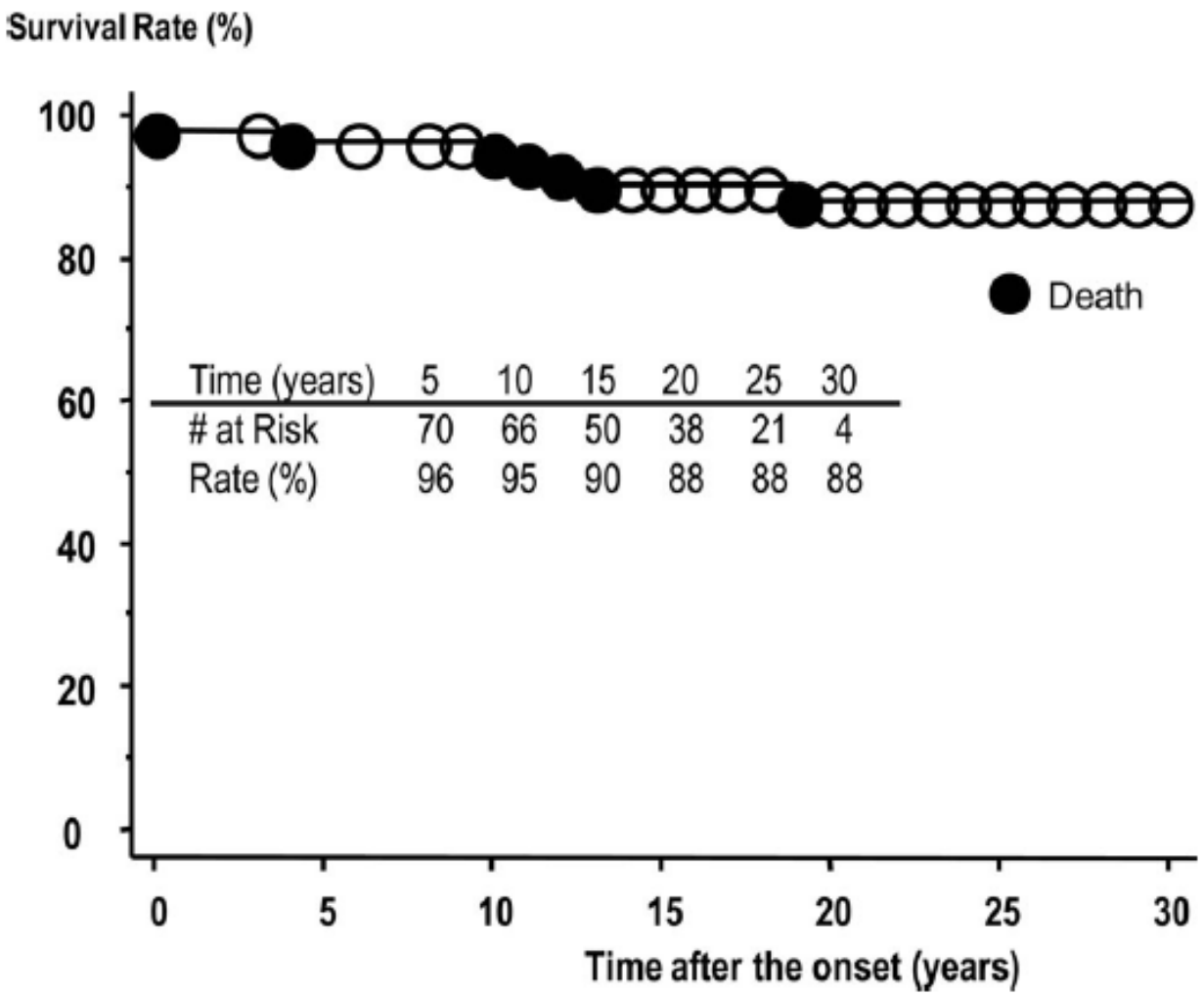

Suda K, et al. Circulation 2011;123:1836

Incidence of Cardiovascular Sequelae Past 15 Years

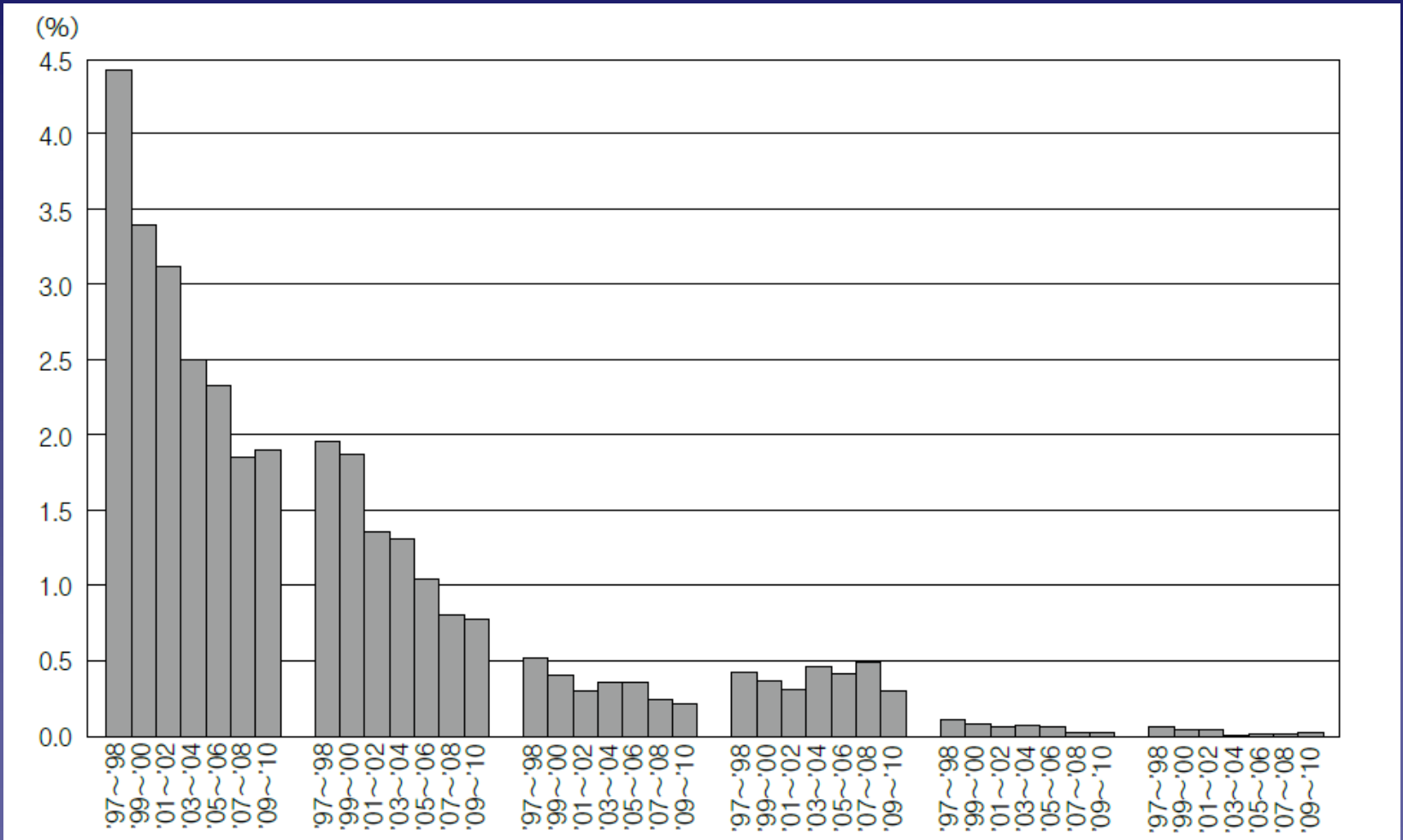

Dilatation Aneurysm Giant An Valve Stenosis MI

Nakamura Y, et al. J Epidemiol 2012

Valvular Involvements after Kawasaki Disease

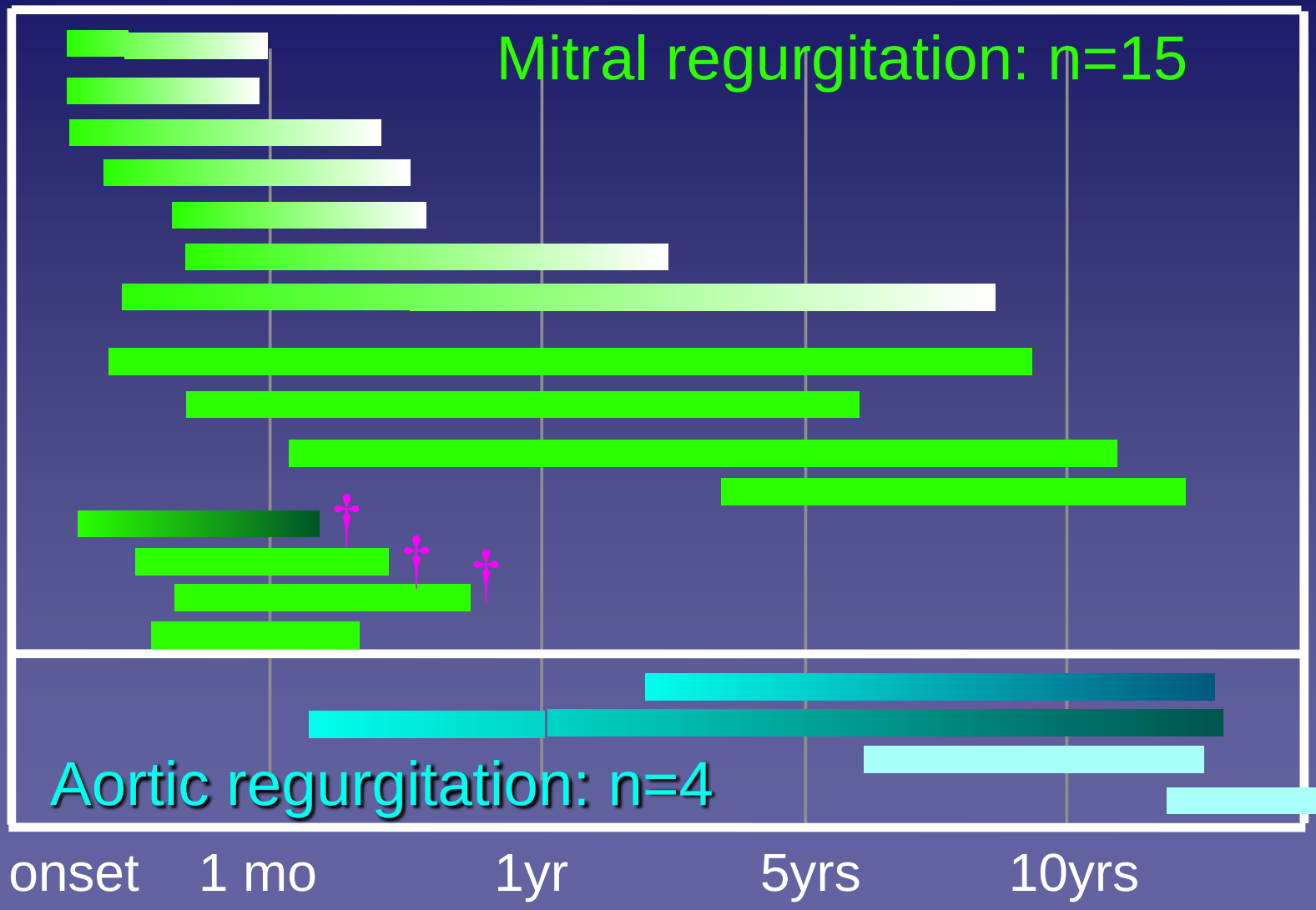

Akagi T, et al: Am Heart J 1990

Optimal therapeutic strategy

Coronary Bypass ?

or

Catheter Intervention ?

Twenty-Five-Year Outcome of Pediatric Coronary Artery Bypass Surgery for Kawasaki Disease

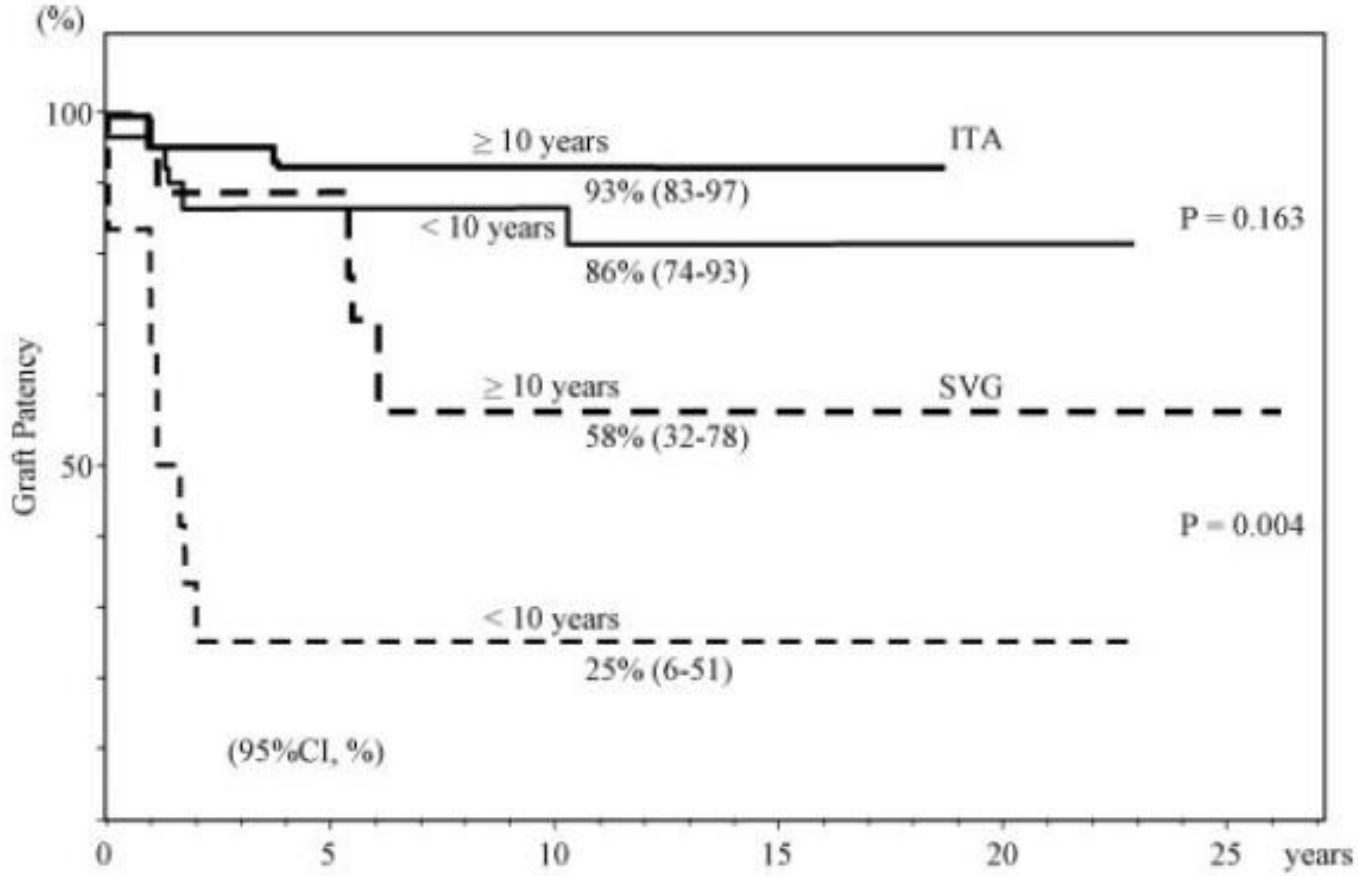

<10 years	66	36	20	7	2		ITA
≥10 years	88	34	16	9			
<10 years	12	3	3	2	2		SVG
≥10 years	18	15	10	4	2	2	

No. at risk

Kitamura S, et al. Circulation 2009; 120:60-69

Rotational Ablation in Kawasaki disease

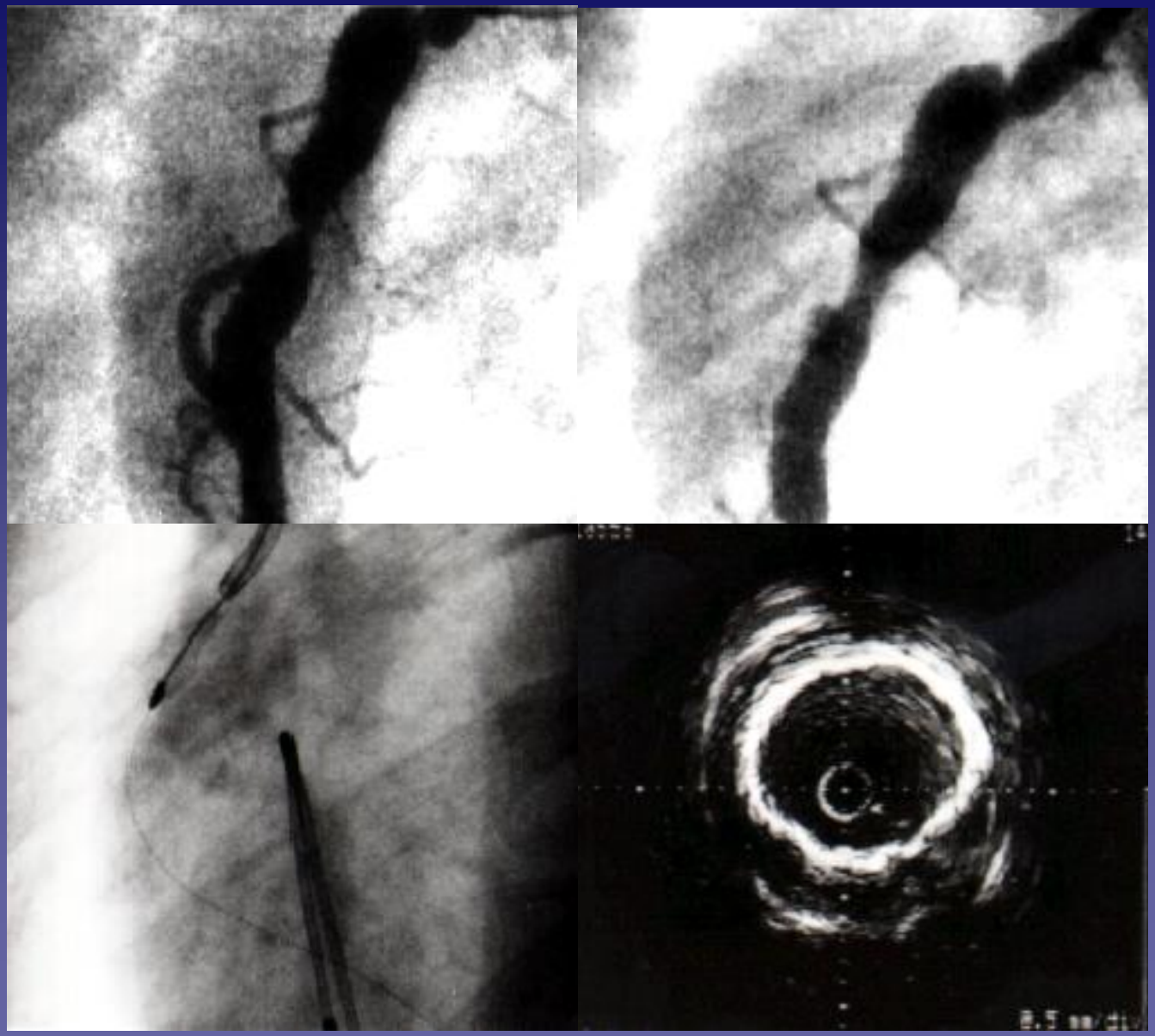

Sugimura T, Akagi T, et al. Circulation 1997

Free from re-intervention ratio

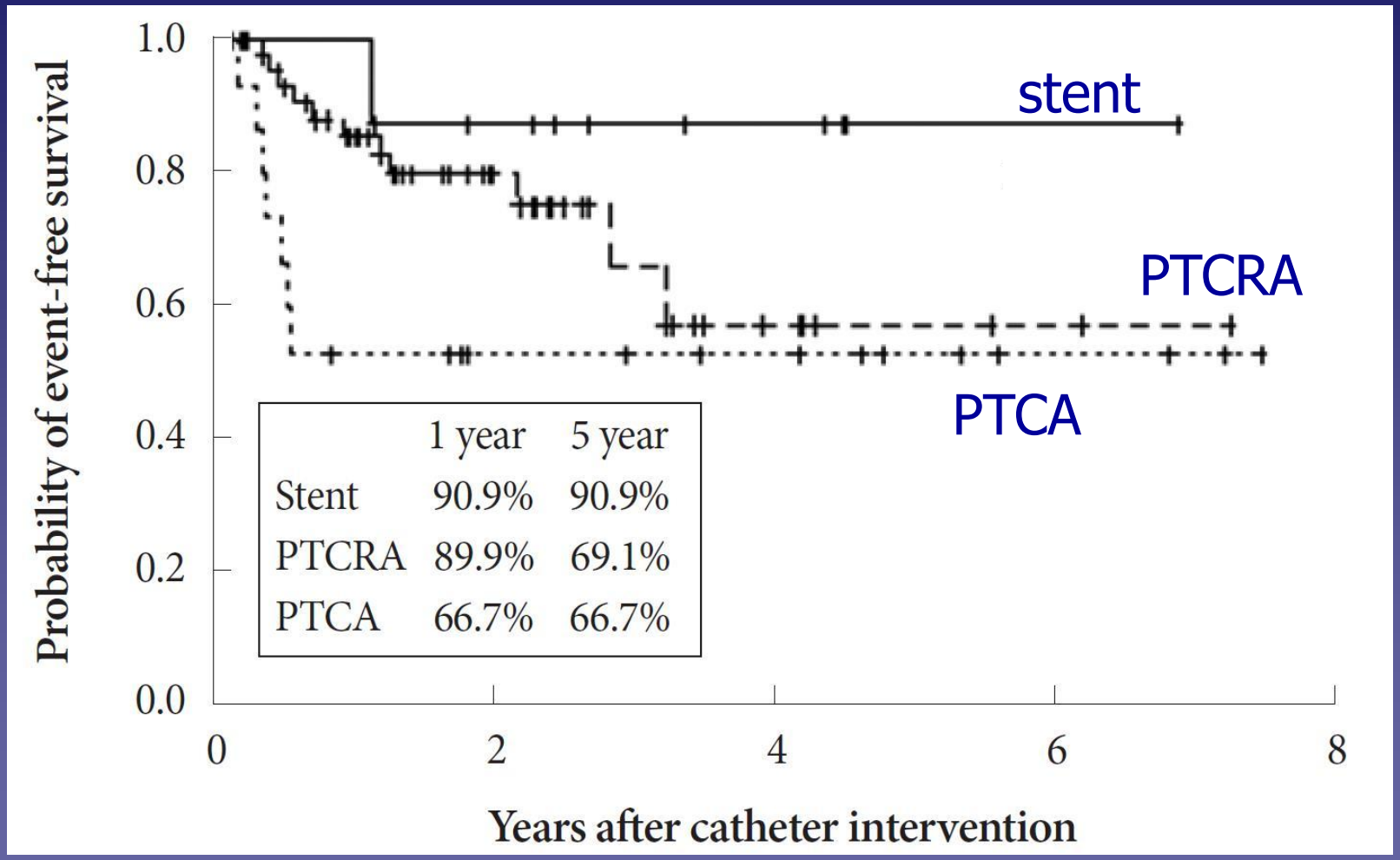

Akagi T. Korean Circ J 2012

Neoaneurysm formation after PTCA

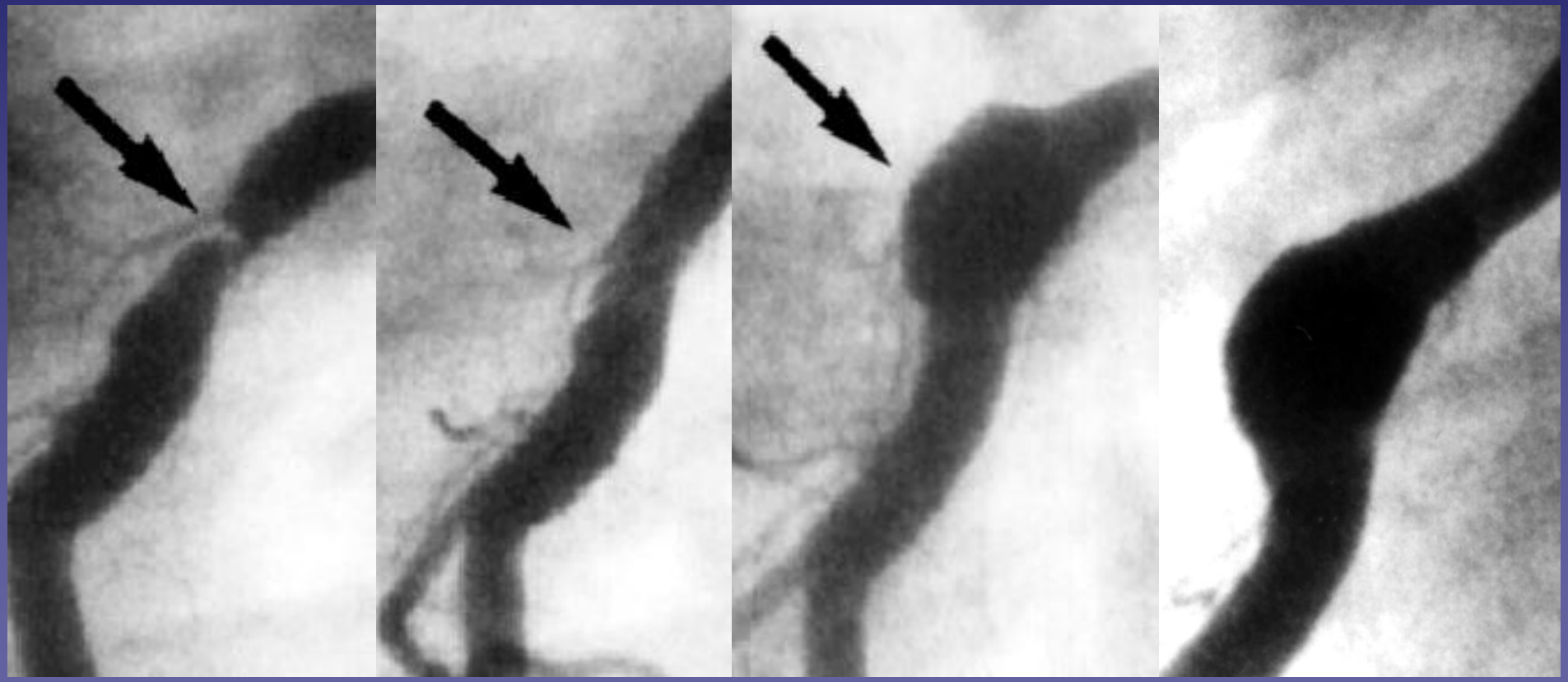

Pre PTCA Post PTCA 4 months after 3 years after

Akagi T, et al. J Pediatr 2002

Coronary Intervention in Adult KD

- **Stiff & calcified lesion**
  - Rotational Ablation
- **Prevention of neoaneurysm formation**
  - Low-Pressure POBA
  - Stent Implantation (optional)
- **Most coronary lesions are complex**
  - Anti-coagulation
- **Most coronary lesions are progressive**
  - Preventive Indication